ISSN 2229-5518

Meckel Gruber Syndrome

Dr. Allybocus Zubair Akbar

Republic of Mauritius

.

Abstract— Meckel Gruber syndrome (MGS) is a rare and lethal autosomal recessive disorder. In clinic, it is suspected once a triad of polydactyly, cystic kidneys and occipital encephalocele are seen upon antenatal ultrasound examination. Though each feature may also be associated with other chromosomal conditions, the triad, or at least two features are highly suggestive of MGS. A definitive diagnosis is obtained by molecular identification of specific genes known for MGS. In this report, we briefly consider the ultrasound findings that are used for diagnosis of MGS in clinic.

Index Terms— Meckel Gruber Syndrome, ultrasound imaging, polydactyly, occipital encephalocele, cystic kidney

1. Introduction

Meckel-Gruber syndrome (MGS) belongs to a condition of ciliopathies, a category of disease thought to be caused by dysfunction of cilia and flagella. These dysfunctions at cellular level will result in anomalies, of variable gravity, in the phenotype of the affected individual. The primary cilium, which is a microtubule-based organelle projecting from the apical surface of vertebrate cells, acts as an "antenna" that receives and transduces chemosensory and mechanosensory signals, and also regulates diverse important signaling pathways, during embryonic development. Though MGS is commonly characterized by the triad of brain malformation (mainly occipital encephalocele), large polycystic kidneys, and polydactyly, other anomalies may include oral cleft, genital anomalies, CNS malformations, Arnold-Chiari malformation, Dandy-Walker, liver fibrosis, Cardiac lesions and pulmonary stenosis. Worldwide, the incidence of MGS is 1 per 13,250–140,000 live births. Individuals of Finnish descent have a higher incidence (1 per 9000 live births, one person in 50 is a carrier). The incidence is also higher among Belgians and Bedouins in Kuwait, with 1 affected birth in 3,500 (carrier rate 1 in 30). The highest incidence is reported in the Gujarati Indians, with 1 affected birth per 1,300 (carrier rate, 1 in 18) [1,2]. We shall briefly consider the clinical findings used in practice to diagnose MGS.

2. Clinical Investigation and Findings

MGS can be accurately suspected, if not diagnosed, by experienced and skilled sonographer during women antenatal examination. The diagnosis can be made at different levels namely at ultrasound imaging and confirmed by molecular analysis. Though not a case report, we shall discuss few diagnostic steps using data of one of our patient. MGS is commonly characterized by posterior fossa abnormalities (most frequently occipital encephalocele) (**Figure 1**), bilateral enlarged cystic kidneys (**Figure 3**), and postaxial polydactyly, usually affecting both hands and feet (**Figure 2**), which is seen in 70–80% of cases [3,4].

2.1 Ultrasound findings

Fetuses with MGS usually survive only few days to a few weeks after birth. Due to its high mortality rate, an early detection is mandatory. Ultrasound imaging by 16 weeks can be used for full fetal anatomy examination by ultrasonography. The triad of occipital encephalocele, cystic kidneys and polydactyly is diagnostic of MGS, until proven otherwise. Therefore ultrasound imaging 2-dimensional (2D), 3-dimensional (3D) and 4-dimensional (4D) imaging have made the

diagnosis easier for less skilled sonographers. Our patient ultrasound imaging findings were as follows; abdominal ultrasound performed on mother revealed an encephalocele in fetal occipital area. There the 3rd

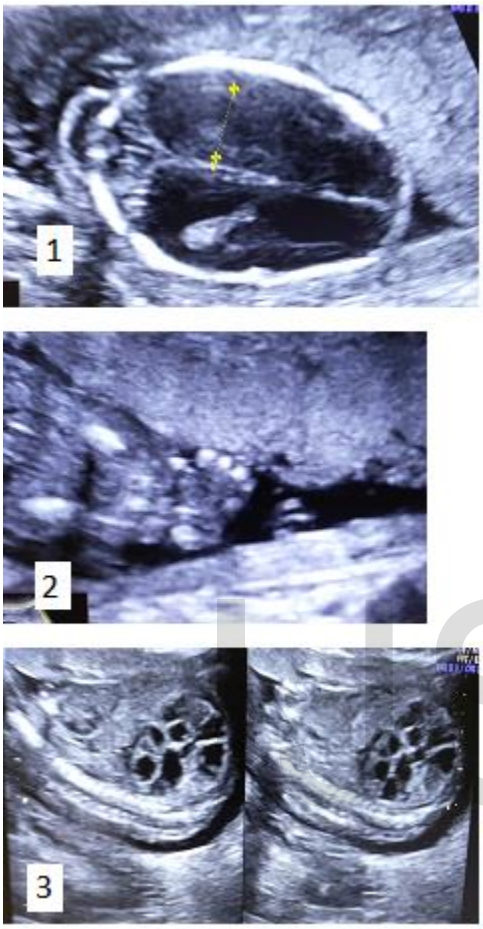

Figure 1 Occipital encephalocele, 2 Polydactyly feet, 3- bilateral Cystic kidneys

ventricles were enlarged but the cisterna magna was not compressed. Fetal neck region examination showed normal NT for gestational age. Organ examination showed normal heart with normal 4 chamber view and vessels. Blood flow in heart was normal. The liver appeared normal. However the kidney had cystic appearance with decreased parenchymal thickness in both kidneys. The bladder was normal in size. Extremities examination revealed polydactyly in feet and hands. From this point, we suspected the diagnosis of MGS. The ultrasound findings were further confirmed after repeating the examination by 2 professors, after which a final diagnosis of MGS was laid. The parents were informed of the medical condition and the most probable outcome of this pregnancy.

2.2 Molecular Findings

MGS should be differentiated from a group of differential diagnosis for ciliopathies namely Joubert syndrome (JBTS), COACH syndrome (cerebellar vermis hypo/ aplasia, oligophrenia, congenital ataxia, ocular coloboma, and hepatic fibrosis), oro-facio-digital syndrome (OFD), nephro-nophthisis (NPHP), and Bardet–Biedl syndrome (BBS). To date, mutations in 14 genes (including *TXNDC15*) are identified as causative for MGS [5]. Molecular analysis is one of the most accurate tool for diagnosis of gene related disorders in our modern society. With molecular analysis, we can detect gene mutation very early in pregnancy by using amniotic fluid or chorionic villus samples. This helps parent-to-be to know about their baby's risk of carrying some mutations when parents are themselves carriers or any *de novo* mutation in fetus.

Prognosis and Treatment

Unfortunately the outcome of MGS is fatal and most fetuses will die soon after birth. Pulmonary hypoplasia is the leading cause of death followed by liver and renal failure. There is currently no treatment *in utero* for the fetuses affected with MGS, while informing the parents that termination of pregnancy is the only solution.

4. Discussion

MGS is lethal *in utero* or immediately after birth, often due to pulmonary hypoplasia, followed by renal and hepatic failures, although one reported survivor has been described aged 28 months [6]. MGS is generally diagnosed by the presence of cystic kidney dysplasia (**Figure 3**), in addition to at least one other hallmark feature of the disease, comprising occipital encephalocele (**Figure 1**),or polydactyly (**Figure 2**). Transabdominal ultrasonography, performed by 10–14 weeks gestation, can successfully detect several of the documented fetal anomalies for MGS including polycystic kidneys (from 9 weeks gestation), occipital encephalocele (from 13 weeks), and polydactyly (from 11 weeks) [7]. Further investigation of anomalies is possible by transvaginal scanning. The fetal bladder can also be visualized by ultrasonography from 11 weeks, and

the absence of a visible fetal bladder is often indicative of renal dysfunction. Definitive diagnosis is possible by using DNA testing to screen for mutations in genes responsible for MGS. Molecular diagnostic strategies include mutation screening of individual genes or targeted clonal sequencing of multi-gene panels. MGS being of AR inheritance pattern, couples with a previously affected child should therefore have genetic counseling about MGS, its recurrence risk in future pregnancies, its outcomes on fetus and parents should be counseled of the purpose of early pregnancy termination once diagnosis is confirmed.

In conclusion, MGS is a rare autosomal recessive condition that has 100% mortality. The diagnosis should be made possible antenatally with modern ultrasound techniques , molecular testing and the parents should be accurately counseled regarding its prognosis on fetus, the recurrence risk in future pregnancies and pregnancy termination options.

Conflict of Interest

The author has declare no conflict of interest

References

[1]. Auber B, Burfeind P, Herold S, Schoner K, Simson G, Rauskolb R, et al. A disease causing deletion of 29 base pairs in intron 15 in the *MKS1* gene is highly associated with the campomelic variant of the Meckel-Gruber syndrome. *Clin Genet* (2007) 72:454–9. doi:10.1111/j.1399-0004.2007.00880.x

[2]. Young ID, Rickett AB, Clarke M. High-incidence of Meckels syndrome in Gujarati Indians. *J Med Genet* (1985) 22:301–4. doi:10.1136/jmg.22.4.301

[3]. Fraser FC, Lytwyn A. Spectrum of anomalies in the Meckel syndrome, or maybe there is a malformation syndrome with at least one constant anom-aly. *Am J Med Genet* (1981) 9:67–73. doi:10.1002/ajmg.1320090112

[4]. Salonen R. The Meckel syndrome – clinicopathological findings in 67 patients. *Am J Med Genet* (1984) 18:671–89. doi:10.1002/ajmg.1320180414

[5]. Verity Hartill1, Katarzyna Szymanska, Saghira Malik Sharif, Gabrielle Wheway and Colin A. Johnson*. Meckel–Gruber Syndrome: An Update on Diagnosis, Clinical Management, and Research Advances. Front Pediatr 2017;5:244.

[6]. Fraser FC, Lytwyn A. Spectrum of anomalies in the Meckel syndrome, or maybe there is a malformation syndrome with at least one constant anom-aly. *Am J Med Genet* (1981) 9:67–73. doi:10.1002/ajmg.1320090112 6. Salonen R. The Meckel syndrome – clinicopathological findings in 67 patients.

[7]. Ramadani HM, Nasrat HA. Prenatal diagnosis of recurrent Meckel syn-drome. *Int J Gynaecol Obstet* (1992) 39:327–32. doi:10.1016/0020-7292(92) 90265-K